



## LASER THERAPY...

- CONTROVERSIAL APPLICATIONS
- MYTHS
- CONTRAINDICATIONS (OR NOT!)
- AND WEIRD WAYS TO USE IT!

---

In this issue, you will find not the typical listings of laser therapy research of how or when laser therapy works or does not work, but rather a collection of information and a few thoughts on novel applications for laser. My intention is also to present information that dispels some falsely propagated myths. Now, if you're a long time Four Leg Subscriber, you'll have noted that over the years, I've have a number of Guest Blogs by Peter Jenkins of SpectraVET lasers. He's my 'go to' expert when it comes to 'outside the box thinking' and laser questions that I scratch my head about. I wanted to put all of his wisdom into one place, along with some additional information I've found over the years. Indeed, also watch the Laser Update Videos on FourLeg.com (Video Training 180 & 182), but again, I wanted this information all in one place for you. My intention is to give you something to reference, and/or handout if needed in order to justify or advance your laser practices. Okay, maybe *I* just want it all in one place!!! Anyways, I hope you enjoy this issue of Four Leg News and may it enhance your clinical laser use and improve your outcomes as well! Cheers!

Laurie Edge-Hughes, BScPT, MAnimSt (Animal Physiotherapy), CAFCI, CCRT

---

# Contraindication or Not?

---

*Can I laser over or near a tumour? Can I laser a patient that has or had cancer?*

---

A recent text book on the subject of laser therapy in veterinary medicine cites that the evidence is conflicting in regards to laser and cancer.

(Godbold & Riegel. Contraindications, Special Considerations and Precautions. In Laser Therapy in Veterinary Medicine: Photobiomodulation. Wiley Blackwell, Iowa, 2017, pp 67 – 73.)

- For safety – no lasering over malignancy or margins
- Might be okay if tumour has been removed and margins are clear
- Current data says “Okay to laser at sites distant to the tumour”
- Considered useful for pain and inflammation in terminal patients
  - Owner involvement in decision to use laser is imperative!
- In vitro studies show that laser might stimulate a tumour
- In vivo studies have actually shown it might be beneficial



It used to be a definitive ‘NO, don’t laser over a tumour.’ There were no in vivo studies that showed it to be safe OR harmful. The tendency was to err on the side of caution. Of course, in more litigious societies, it could still be said to be a hard ‘No’...

At this point, I’d like to refer back to a Guest Blog on FourLeg.com. I’ll reprint it here:

## **Blog – Can I laser for Osteosarcoma?**

<https://fourleg.com/Blog/343/Guest-Blog---Can-I-Laser-for-Osteosarcoma?>

Published March 4, 2018

By Peter Jenkins, MBA– [www.spectravet.com](http://www.spectravet.com)

The question of laser therapy (aka low level laser therapy – LLLT or photobiomodulation therapy - PBMT) vs cancer is a common one, and, typically, you’ll see cancer and neoplasia listed as contraindications for laser therapy.

However, it’s not always the case that laser treatment should be withheld from patients with known or suspected cancer, nor that irradiation of a tumor mass itself is necessarily contraindicated.

There is nothing in the literature specifically regarding laser therapy and osteosarcoma, but there are studies

with other cancers. There are also numerous studies into the benefits of PBMT in the treatment and prevention of oral mucositis in patients undergoing radiation and chemotherapy for e.g. leukemia, head and neck cancer, lymphoma, and acute lymphoblastic leukemia, all of which demonstrate safety and efficacy.

I would take every case individually, of course, but, as a general rule, using LLLT/PBMT on patients with known or suspected neoplasia or tumors is not specifically contraindicated, and post-op PBMT following tumor removal would probably be more beneficial than not; possibly even if the margins aren't clean.

When in doubt, you could utilize distal/systemic effects by irradiating regional lymph nodes, and also any volume of tissue through which blood flows to the surgical site. You can also irradiate between the spinal segments over the applicable dorsal roots.

On a cautious note, borne from experience with our own dog, Phoenix, who we lost to osteosarcoma in 2016, I would be careful irradiating directly over the lesion site, at least initially.

We initially thought P-dog had muscle soreness due to some rough-housing with a Cane Corso we'd fostered. After consulting with our vet, who uses laser in his practice, we started lasering Phoenix's shoulder and upper leg. However, whenever I irradiated the upper end of the humerus he'd flinch and withdraw in obvious pain.

In 19 years (at that time) I'd never seen a reaction like this. I tried a non-contact technique, but it made no difference. I thought it quite significant, too, that he did not react when the laser was applied but not switched on.

This led us back to the vet, who performed a biopsy. Unfortunately, we got the news we'd been wishing we wouldn't.

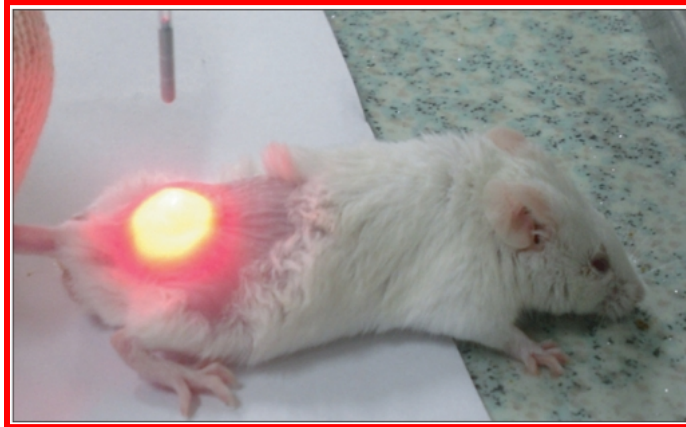Now, a single case isn't much to go by, and I don't know whether, in our case, laser irradiation was causative in relation to P-Dog's increased pain, but I suspect it was. So now I advise that, if a patient reacts to laser application with an immediate increase in pain, do some more digging.

From the literature:

***In Vitro:*** There's been a number of studies [Sperandio et al, 2013 (1); Gomes Henriques et al, 2014 (2)] which have shown that laser irradiation can cause tumor cell proliferation, while others [Schartinger et al, 2012 (3); Berns 1988 (4); McGuff, 1965 (5), 1966 (6) & 1966 (7)] have found that laser therapy does not exhibit a tumor-promoting effect.

***In Vivo:*** Three studies [Frigo et al, 2009 (8); Rhee et al, 2016 (9); Ottaviani et al, 2016 (10)] have demonstrated that tumor mass can increase after laser irradiation in vivo, but, in two of these [Frigo et al, 2009 (8); Ottaviani et al, 2016 (10)], anti-cancer effects were also shown.

Thank you to  
the mice!



Frigo et al (8) studied an in vivo mouse model of melanoma. A control group (n=7) received no irradiation. The active groups received daily transdermal irradiation for three days with a 50 mW continuous wave 660 nm laser, beam spot 0.02 cm<sup>2</sup> (2.5 W/cm<sup>2</sup>), at two doses:

- a. Low-Dose Group (n=7) was irradiated for 60 secs and received 3 J (150 J/cm<sup>2</sup>) per treatment session. Tumors in the low-dose group reduced (insignificantly) in size compared to the control group.
- b. High-Dose Group (n=7) was irradiated for 420 secs and received 21 J (1050 J/cm<sup>2</sup>) per treatment session. The total tumor mass volume in this group increased significantly versus control.

Rhee et al (9) studied an in vivo mouse model of human anaplastic thyroid carcinoma. A control group (n=10) received no irradiation. The two active groups each received a single direct irradiation to the surgically-exposed thyroid with a 2 mW continuous wave 650 nm laser, beam spot 0.02 cm<sup>2</sup> (100 mW/cm<sup>2</sup>), at two doses:

- a. Low-Dose Group (n=10) was irradiated for 150 secs and received 0.3 J (15 J/cm<sup>2</sup>). Tumors in the low-dose group increased significantly in size compared to the control group.
- b. High-Dose Group (n=10) was irradiated for 300 secs and received 0.6 J (30 J/cm<sup>2</sup>). The total tumor mass volume in this group increased significantly versus both control and the low-dose group.

Ottaviani et al (10) studied both melanoma and oral carcinoma in mice, with three different sets of laser parameters:

- a. L1: Wavelength 660 nm, laser power 100 mW, irradiance 50 mW/cm<sup>2</sup>, fluence 3 J/cm<sup>2</sup>, time 60 s, continuous wave.
  - b. L2: Wavelength 800 nm, laser power 1 W, irradiance 200 mW/cm<sup>2</sup>, fluence 6 J/cm<sup>2</sup>, time 30 s, continuous wave.
  - c. L3:  $\lambda$  970 nm, laser power 2.5 W, irradiance 200 mW/cm<sup>2</sup>, fluence 6 J/cm<sup>2</sup>, time 30 s, continuous wave.
- Irradiation was performed daily for four days. A control group for each of the cancer types received no irradiation. Tumor growth continued in all active groups, but the growth rates of the tumors were significantly decreased in all groups versus control. This result was attributed to a 'normalisation' of tumor vasculature and an increase in immune cell activation.

---

### References:

1. Sperandio et al (2013) Low-level laser therapy can produce increased aggressiveness of dysplastic and oral cancer cell lines by modulation of Akt/mTOR signaling pathway. *J Biophotonics*. 2013 October ; 6(10): 839-847
2. Gomes Henriques et al (2014) Low-level laser therapy promotes proliferation and invasion of oral squamous cell carcinoma cells. *Lasers Med Sci* (2014) 29:1385-1395

3. Schartinger et al (2012) Differential responses of fibroblasts, non-neoplastic epithelial cells, and oral carcinoma cells to low-level laser therapy. Abstract:<https://www.ncbi.nlm.nih.gov/pubmed/21340656>
  4. MW Berns, JS Nelson. Laser applications in biomedicine. Part I: biophysics, cell biology, and biostimulation J Laser Appl 1988;1:34-39.
  5. PE McGuff, RA Deterling Jr, LS Gottlieb. Tumorcidal effect of laser energy on experimental and human malignant tumors. New Engl J Med 1965;273:490-492.
  6. PE McGuff, RA Deterling Jr, LS Gottlieb. Laser radiation for metastatic malignant melanoma. JAMA 1966;195:393-394.
  7. PE McGuff, LS Gottlieb, I Katayama, CK Levy. Comparative study of effects of laser and/or ionizing radiation therapy on experimental or human malignant tumors. Am J Roentgenol Radium Ther Nucl Med 1966;96:744-748.
  8. Frigo L, Luppi JS, Favero GM, et al. The effect of low-level laser irradiation (In-Ga-Al-AsP - 660 nm) on melanoma in vitro and in vivo. BMC Cancer. 2009;9(1):404-408. doi:10.1186/1471-2407-9-404
  9. Rhee Y-H, Moon J-H, Choi S-H, Ahn J-C (2016) Low-Level Laser Therapy Promoted Aggressive Proliferation and Angiogenesis Through Decreasing of Transforming Growth Factor-b1 and Increasing of Akt/Hypoxia Inducible Factor-1a in Anaplastic Thyroid Cancer. Photomed Laser Surg 34:229-235
  10. Ottaviani et al (2016) Laser Therapy Inhibits Tumor Growth in Mice by Promoting Immune Surveillance and Vessel Normalization. EBioMedicine 11 (2016) 165-172
- 

Currently on the home front, my husband and I faced with the decision to laser his carcinoid tumour or not. (Full disclosure, this would be a Home Remedy.) I've been looking on PubMed to see what literature is available and I've come across a review paper on the subject!

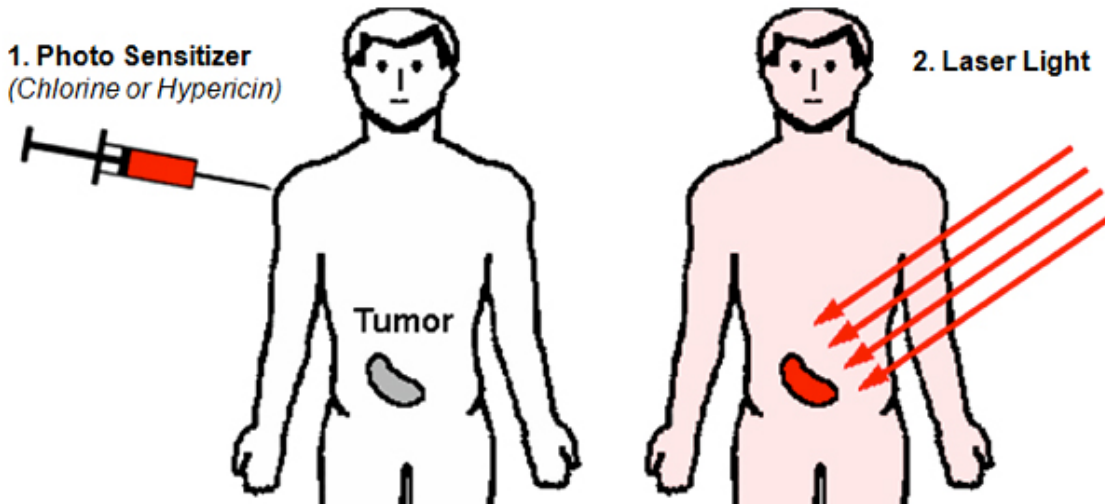
## Photodynamic Therapy of Cancer: An Update

Patrizia Agostinis, PhD<sup>1</sup>; Kristian Berg, PhD<sup>2</sup>; Keith A. Cengel, MD, PhD<sup>3</sup>; Thomas H. Foster, PhD<sup>4</sup>; Albert W. Girotti, PhD<sup>5</sup>; Sandra O. Gollnick, PhD<sup>6</sup>; Stephen M. Hahn, MD, PhD<sup>7</sup>; Michael R. Hamblin, PhD<sup>8,9,10</sup>; Asta Juzeniene, PhD<sup>11</sup>; David Kessel, PhD<sup>12</sup>; Mladen Korbely, PhD<sup>13</sup>; Johan Moan, PhD<sup>14,15</sup>; Pawel Mroz, MD, PhD<sup>16,17</sup>; Dominika Nowis, MD, PhD<sup>18</sup>; Jacques Piette, PhD<sup>19</sup>; Brian C. Wilson, PhD<sup>20</sup>; Jakub Golab, MD, PhD<sup>21,22</sup>

### Abstract

Photodynamic therapy (PDT) is a clinically approved, minimally invasive therapeutic procedure that can exert a selective cytotoxic activity toward malignant cells. The procedure involves administration of a photosensitizing agent followed by irradiation at a wavelength corresponding to an absorbance band of the sensitizer. In the presence of oxygen, a series of events lead to direct tumor cell death, damage to the microvasculature, and induction of a local inflammatory reaction. Clinical studies revealed that PDT can be curative, particularly in early stage tumors. It can prolong survival in patients with inoperable cancers and significantly improve quality of life. Minimal normal tissue toxicity, negligible systemic effects, greatly reduced long-term morbidity, lack of intrinsic or acquired resistance mechanisms, and excellent cosmetic as well as organ function-sparing effects of this treatment make it a valuable therapeutic option for combination treatments. With a number of recent technological improvements, PDT has the potential to become integrated into the mainstream of cancer treatment. *CA Cancer J Clin* 2011;61:250-281. © 2011 American Cancer Society, Inc.

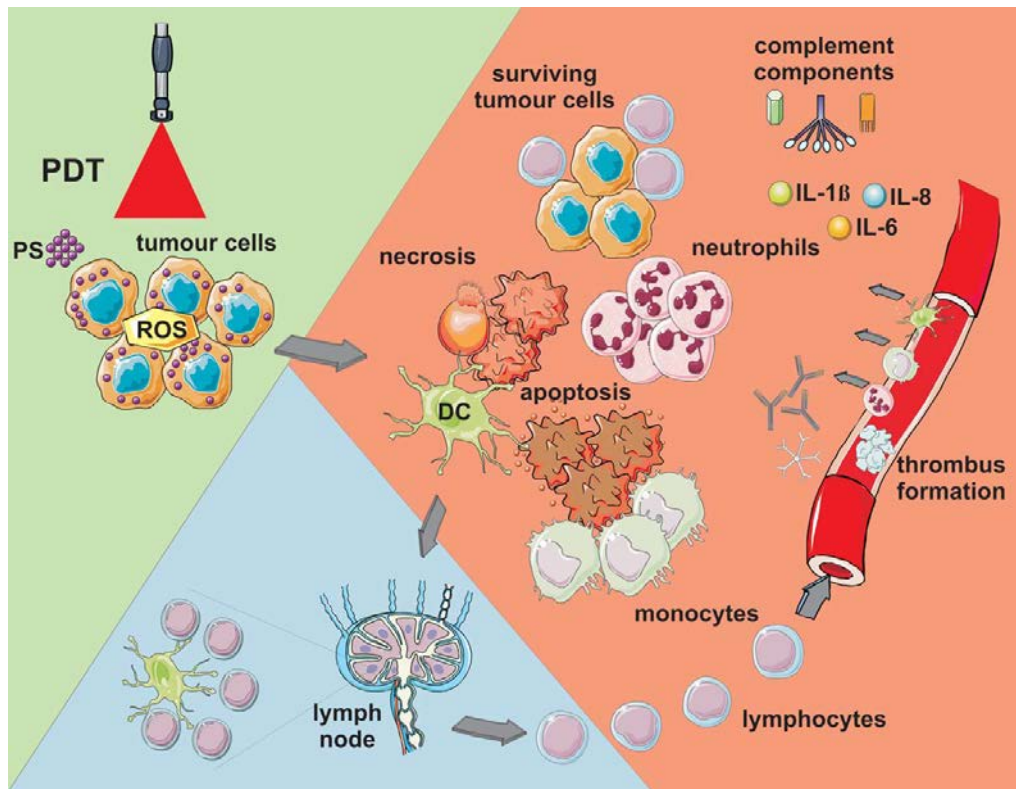
Essentially, what research is currently looking at is the use of laser after injection of a Photo Sensitizing agent. Then, when you direct the laser light at the target tissue, that location is more sensitive to the laser light. (However some papers are not so specific about the need for a photosensitizing agent... but something as simple as chlorophyll might do the trick!)



The paper cites the following pathways in regards to therapeutic benefit.

- 1) Anti-vascular effects may result with photodynamic therapy (PDT). This one was hard for me to wrap my head around, but essentially, the paper cited other papers where they found that laser was absorbed by endothelium of the blood vessels supplying the tumour resulting in a blanching and vasoconstriction of the vessels and subsequent hypoxia-induced tumour cell death. However, normal tissues could be adversely affected as well.
- 2) Activation of an immune response with PDT. PDT frequently provokes a strong acute inflammatory reaction characterized by local edema at the target site. This prompts the body to launch protective actions in order to protect homeostasis and tissue integrity. As this occurs the body is alerted to damaged or diseased cells which can then be removed. PDT may be particularly effective in rapidly generating an abundance of alarm/danger signals that can be detected by the innate immune system. The inflammatory cells, led by neutrophils and followed by mast cells and monocytes/macrophages, rapidly and massively invade tumors undergoing PDT. Damage and dysfunction of photodynamically treated tumor vasculature frequently results in vascular occlusion that serves to “wall off” the damaged tumor tissue until it is removed by phagocytosis, thereby preventing the spread of the disrupted homeostasis.

Furthermore, photodynamic therapy works well with all other therapies typically utilized with cancer treatment.



**FIGURE 5.** Photodynamic Therapy (PDT)-Induced Effects. Light-mediated excitation of photosensitizer (PS)-loaded tumor cells leads to the production of reactive oxygen species (ROS) within these cells, leading to cell death (predominantly apoptotic and necrotic). Tumor cell kill is further potentiated by damage to the microvasculature (not shown), which further restricts oxygen and nutrient supply. Tumor cell death is accompanied by activation of the complement cascade; secretion of proinflammatory cytokines; and rapid recruitment of neutrophils, macrophages, and dendritic cells (DCs). Dying tumor cells and tumor cell debris are phagocytosed by phagocytic cells, including DCs, which migrate to the local lymph nodes and differentiate into professional antigen-presenting cells. Tumor antigen presentation within the lymph nodes is followed by clonal expansion of tumor-sensitized lymphocytes that home to the tumor and eliminate residual tumor cells. IL indicates interleukin.

Furthermore, additional review papers have concluded that photobiomodulation therapy might help restore homeostasis and homeokinesis in cancer patients. It is proposed that by re-establishing physiological rhythms and inducing physiologically reparative effects for disease reversal in cancer and other complex diseases, laser therapy might provide significant improvements in quality of life, even in more advanced neoplasms.

Santana-Blank L, et al. Solid tumors and photobiomodulation: a novel approach to induce physiologically reparative homeostasis/homeokinesis – review. *J Solid Tumors*. 2012, 2(6):623-635.

Santana-Blank L, Rodríguez-Santana E, Santana-Rodríguez KE, Reyes H. "Quantum Leap" in Photobiomodulation Therapy Ushers in a New Generation of Light-Based Treatments for Cancer and Other Complex Diseases: Perspective and Mini-Review. *Photomed Laser Surg*. 2016 Mar;34(3):93-101.

# Contraindication or Not?

*Can I laser over growth plates? Should I be cautious in lasering around or near joints in young, growing dogs?*

To address this question, I point the reader back to a blog post I wrote in January of 2018. <https://fourleg.com/Blog/335/Laser-and-Growth-Plates> At that time, I dug around the research a bit to answer exactly this question!

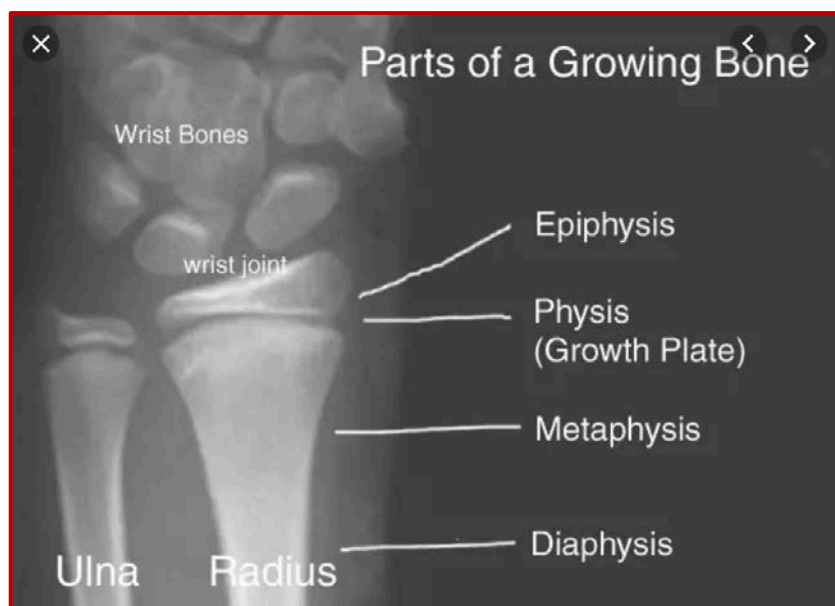
## **Blog – Laser and Growth Plates**

Published January 7, 2018

By Laurie Edge-Hughes

Not so long ago we had a surgeon state that all of the lasering we had been doing to one of his patients had caused the growth plates to close prematurely. It was a young dog, for whom we were providing pre-hab for a torn ACL while we waited for growth plates to close in order for a TPLO to be performed.

So, 1) feeling horrible that this could be true, and 2) wanting to combat the accusation, I went to my trusty friend PubMed to see what she had to say. (P.S. I figure Pubmed is a 'she'. No reason, just because...)





I found three recent papers that looked at growth plate closure and laser therapy.

**The first paper:**

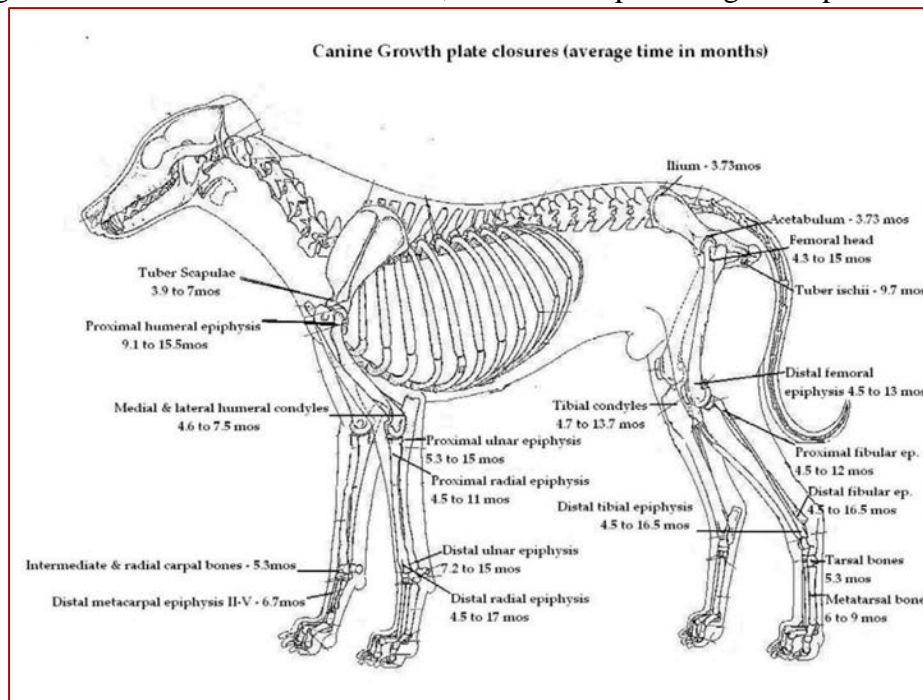
Scientific World Journal. 2012;2012:231723. doi: 10.1100/2012/231723. Epub 2012 Apr 30.

**The effects of low-level laser therapy, 670 nm, on epiphyseal growth in rats.**

de Andrade AR1, Meireles A, Artifon EL, Brancalhão RM, Ferreira JR, Bertolini GR.

The longitudinal growth of long bones is attributed to epiphyseal growth. However, the effects of low-level laser therapy (LLLT) in such structures has still not been studied extensively in the literature. Therefore, the aim of this study was to evaluate the use of LLLT, **670 nm, at three different doses on the epiphyseal growth of the right tibia of rats.** Twenty-one Wistar rats, aged four weeks, were subjected to the application of LLLT, with dosage according to the group (**G4: were submitted to the application of 4 J/cm(2); G8: were submitted to the application of 8 J/cm(2); G16: were submitted to the application of 16 J/cm(2).**) After completion of protocol they were kept until they were 14 weeks of age and then submitted to a radiological examination (evaluation of limb length) and euthanised. The histological analysis of the growth plates (total thickness and hypertrophic and proliferative zones) was then performed. **Comparisons were made with the untreated left tibia. No differences were observed** in any of the reviews (radiological and histological), when comparing the right sides (treated) to the left (untreated). *It was concluded that the treatment with LLLT within the parameters used caused changes neither in areas of the epiphyseal cartilage nor in the final length of limbs.*

**Thoughts:** So this is a 670nm laser. It doesn't penetrate much past 0.5cm, and this wavelength is better targeted at skin lesions. Nevertheless, it did not impact the growth plates.



### The second study:

Photomed Laser Surg. 2010 Aug;28(4):527-32. doi: 10.1089/pho.2009.2572.

#### **Effect of GaAlAs laser irradiation on the epiphyseal cartilage of rats.**

Cressoni MD1, Giusti HH, Pião AC, de Paiva Carvalho RL, Anaruma CA, Casarotto RA.

#### OBJECTIVE:

To study the effect of an **830-nm gallium-aluminum-arsenic (GaAlAs) diode laser at two different energy densities (5 and 15 J/cm<sup>2</sup>) on the epiphyseal cartilage of rats** by evaluating bone length and the number of chondrocytes and thickness of each zone of the epiphyseal cartilage.

#### BACKGROUND DATA:

Few studies have been conducted on the effects of low-level laser therapy on the epiphyseal cartilage at different irradiation doses.

#### MATERIALS AND METHODS:

A total of 30 male Wistar rats with 23 days of age and weighing 90 g on average were randomly divided into 3 groups: control group (CG, no stimulation), G5 group (energy density, 5 J/cm<sup>2</sup>), and G15 group (energy density, 15 J/cm<sup>2</sup>). **Laser treatment sessions were administered every other day for a total of 10 sessions.** The animals were killed 24 h after the last treatment session. Histological slides of the epiphyseal cartilage were stained with hematoxylin-eosin (HE), photographed with a Zeiss photomicroscope, and subjected to histometric and histological analyses. Statistical analysis was performed using one-way analysis of variance followed by Tukey's post hoc test. All statistical tests were performed at a significance level of 0.05.

#### RESULTS:

Histological analysis and x-ray radiographs revealed an increase in thickness of the epiphyseal cartilage and in the number of chondrocytes in the G5 and G15 groups.

#### CONCLUSION:

**The 830-nm GaAlAs diode laser, within the parameters used in this study, induced changes in the thickness of the epiphyseal cartilage and increased the number of chondrocytes, but this was not sufficient to induce changes in bone length.**

**Thoughts:** So this is a more appropriate laser wavelength, and more closely related to what we use in clinical practice. The use (every second day) is also a bit closer to clinical practice, albeit a more concentrated schedule than what clinical practice employs. There were cartilage changes (but the same changes occur with exercise and cartilage loading). The downside of this study is that it only last for 10 days and the animals were evaluated immediately after the 10-day protocol. A long-term study would have been interesting.



**The last paper:**

Acta Cir Bras. 2012 Feb;27(2):117-22.

**Low-level laser on femoral growth plate in rats.**

Oliveira SP1, Rahal SC, Pereira EJ, Bersano PR, Vieira Fde A, Padovani CR.

**PURPOSE:**

To determine the influence of low-level laser therapy on femoral growth plate in rats.

**METHODS:**

Thirty male Wistar rats aged 40 days were divided into two groups, G1 and G2. In G1 the area of **the distal growth plate of the right femur was irradiated at one point using GaAlAs laser 830 nm wavelength, output power of 40 mW, at an energy density of 10 J/cm<sup>2</sup>**. The irradiation was **performed daily for a maximum of 21 days**. The same procedure was done in G2, but the probe was turned off. Five animals in each group were euthanized on days 7, 14 and 21 and submitted to histomorphometric analysis.

**RESULTS:**

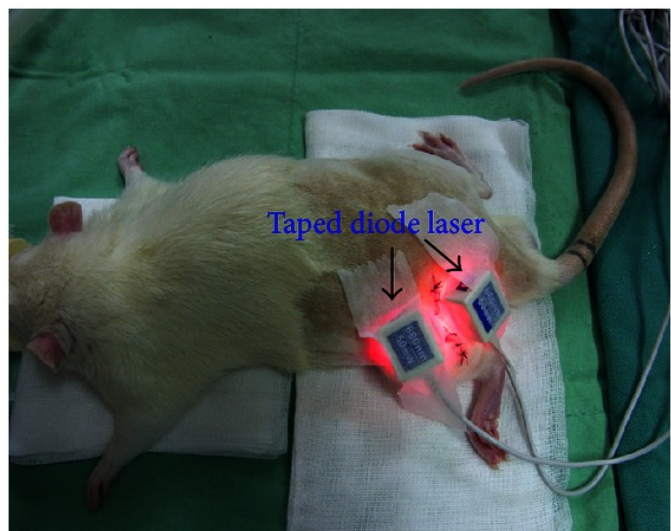
In both groups the growth plate was radiographically visible at all moments from both craniocaudal and mediolateral views. On the 21st day percentage of femoral longitudinal length was higher in G2 than G1 compared to basal value while hypertrophic zone chondrocyte numbers were higher in G1 than G2. Calcified cartilage zone was greater in G1 than in G2 at all evaluation moments. Angiogenesis was higher in G1 than in G2 at 14th and 21st days.

**CONCLUSION:**

**The low-level laser therapy negatively influenced the distal femoral growth plate.**

**Thoughts:** This is a very interesting study, and it does indicate that DAILY use of laser at a more appropriate therapeutic dose and wavelength, caused a reduction in limb growth. This study was extended for longer, that study #2, which may explain why study #2 saw no effect.

Overall thoughts: We do likely have to be cautious with being overzealous about lasering over active growth plates. Obviously, it would be great to see a study that would look at weekly or even twice-weekly lasering over an active growth plate, and extend the study for longer. All in all, we don't have a definitive answer for what to do in clinical practice. I would lean towards being 'okay' to laser on a weekly basis as need be, on a risk vs reward evaluation, but that's me!



## More on Growth Plates?

A follow up blog was written by my laser-guru, Peter Jenkins, MBA from SpectraVET. Here it is for your further knowledge.

### Guest Blog - LLLT/PBM vs Active Epiphyses

<https://fourleg.com/Blog/336/Guest-Blog---LLLTPBM-vs-Active-Epiphyses>

Published January 14<sup>th</sup>, 2018

by Peter A Jenkins, MBA

[www.Spectravet.com](http://www.Spectravet.com)

A frequently-recurring question regarding the clinical use of Laser Therapy is whether treating over active epiphyses is contraindicated.

The general list of contraindications to Low-Level Laser Therapy (LLLT) – now, formally, Photobiomodulation (PBM) – in physiotherapy has largely been carried over from other active modalities, such as ultrasound and e-stim, and accepted without question and with an overabundance of caution, as applying to laser therapy in general.

The use of laser over or near the active epiphysis seems – originally, at least – to have fit this category; it is often listed in device operating manuals and by clinical educators in various fields as being contraindicated, but it is also, equally, stated by others (myself included) to be of no great concern.

### What is the real story?

In 2010, the Canadian Physiotherapy Association published ‘ELECTROPHYSICAL AGENTS Contraindications and Precautions: An Evidence-Based Approach to Clinical Decision Making in Physical Therapy’<sup>1</sup>. According to this document, LLLT/non-coherent light is considered to be safe to use “on skin overlying active epiphysis”, and “can be applied with caution” to the active epiphysis.



To my knowledge, this is the first – and, possibly, only – formal guidance document of this type to address the safety of Low Level Laser Therapy/Photobiomodulation in an evidence-based manner, and its recommendations for physiotherapists were, contemporaneously, accurate and well-founded. However, not all the recommendations are, necessarily, applicable to other specialties, nor – as we’ll now see – is the recommendation about epiphyses still current.

I conducted a search of PubMed, Google Scholar, ResearchGate, and a number of laser- and photobiomodulation-related Journal websites and texts, for various combinations of the key words ‘laser’, ‘laser therapy’, ‘LLLT’, ‘photobiomodulation’, ‘PBM’, ‘epiphysis’, ‘epiphyses’, ‘epiphyseal’, and ‘growth plate’, and turned up relatively few relevant articles<sup>2-11</sup>, one indirectly relevant paper<sup>12</sup>, and a number of false positives. Two of these false positives<sup>13, 14</sup> are often, inappropriately, cited in lay discussion as ‘evidence’ of the negative impact of laser therapy on active epiphyses.



When the CPA document was published in 2010, the only readily-available literature was that regarding a study by Cheetham et al (1992)<sup>2</sup> in which the effects of laser therapy over active epiphyses were investigated. In 2002, Navratil et al<sup>3</sup> referred to this study when stating that “the fear of possible damage to the epiphyseal slots in children in the case of the application of therapeutic laser is baseless”. Other work<sup>4,5</sup> had been done at the time, but accessibility of the literature was limited due to it having only been published in the Russian language.

In the years since 2010, six more directly-relevant papers<sup>6-11</sup> have been published, along with another<sup>12</sup> that contains pertinent information, albeit from within a different field. The various studies shed more light on the effects of LLLT/PBM on epiphyseal growth, but the results remain somewhat controversial.

For example, de Andrade<sup>8</sup> and Handayani<sup>11</sup> found no significant effects on the histology of the epiphyseal cartilage or the final length of limbs, but Cressoni<sup>7</sup> showed that laser irradiation may improve cartilage structure in rats, while Seifi<sup>6</sup>, Oliveira<sup>9</sup> and Yeom<sup>10</sup> all found significant histological and histomorphometric changes, particularly within the hypertrophic zone, and changes in bone length. Oliveira<sup>9</sup> found that the femoral longitudinal length decreased, whereas Yeom<sup>10</sup> found an increased rate of growth. And, while investigating the impact of photodynamic therapy upon epiphyseal plates, Kurchenko<sup>12</sup> found that laser irradiation without the introduction of a photosensitiser led to intracellular swelling of epiphyseal plates chondrocytes.

A major confounding factor, when considering these findings in relation to our initial question, is that each of these studies was conducted with widely differing device and treatment parameters, and the devices used bear scant resemblance to any currently in clinical use.

Where reported, the ‘stationary contact’ application technique was consistent among all studies, but the number of points irradiated and the number of irradiations performed over time varied greatly. Output powers ranged from 4 to 100 mW, power densities from 2 to 563 mW/cm<sup>2</sup>, irradiation durations from 8.5 secs to 8 minutes, wavelengths from 635 to 904 nm, and dosimetry was all over the shop! (Table 1. Parameters)

Essentially, there is little basis for meaningful comparison of these studies, other than they were investigating effects upon similar tissues by applying laser light to similar anatomical locations.

Two studies<sup>10,11</sup> treated acupuncture points, rather than specific anatomical locations over the growth plates. However, two of the points used – ST36 and SP6 – are located adjacent to growth plates; ST36 about 1 mm lateral of the tibial tuberosity, and SP6 a few mm above the medial malleolus on the posterior border of the medial aspect of the tibia. Perhaps unsurprisingly, irradiation over these points elicited greater changes than irradiation of GV20, which is located at the peak of the head, midpoint of a line connecting the apexes of the two auricles. (Figure 1)

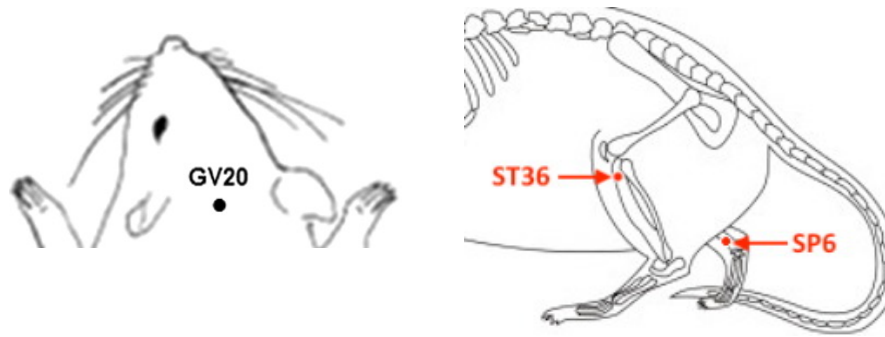


Figure 1. Acupoints GV20, ST36 and SP6 on the rat

Although some studies found no effects of laser irradiation – at the parameters used – upon active epiphyses in rats and hamsters, others did, so there is certainly evidence of effects such as increased angiogenesis, increased proliferation of chondrocytes, and increased calcification.

Not all of the potential effects of LLLT/PBM on growth plates are, necessarily, negative. Yeom et al<sup>10</sup>, for example, conclude that longitudinal bone growth induced by laser acupuncture [to points directly over growth plates] “may have a clinical potential in promoting longitudinal bone growth in children”, and Seifi et al<sup>6</sup> suggest that “laser irradiation with the chosen parameters can stimulate condylar growth and subsequently cause mandibular advancement [...] for further improvement of mandibular retrognathism”. Mavrigh and Luzin<sup>4</sup> state that that laser can be used for the optimisation of growth, mineralization and stability of skeleton bones.

Where does this leave us?

Even with these new data, it is only clear that there is still no clear answer to our question. Yes, there is evidence of effects of LLLT/PBM upon active epiphyses, and in some cases, this may prove to be strongly contraindicated. What is not addressed by any these studies, however, is the relative benefit or otherwise of utilising LLLT/PBM in young patients versus withholding treatment due to concerns over the impact to growth plates; what’s best for each patient must take priority, and there is bound to be many instances where, despite any possible risks, LLLT/PBM is strongly indicated. In all cases, therefore, a cautious and well-considered approach is recommended.

With more information, we can make better-informed clinical choices, although, with the current data, it is not possible to determine an upper or lower margin for any of the important parameters, nor to accurately define a ‘window’ of effect.

However, and if one doesn’t look too closely at the weeds and seeds, it might be possible to find a ‘big picture’ pattern among the data suggesting that (a) more frequent treatments with higher intensities and/or doses over longer periods are more likely to have deleterious effects, than (b) less-frequent treatments with lower intensities/doses over shorter periods. It is worth noting, too, that no studies have yet considered the effect of high-powered (i.e. Class 4 or IV) ‘therapeutic’ lasers and/or very high doses.

NB. I have not made any general statements about a ‘safe’ or otherwise number of J/cm<sup>2</sup>, as this is a relatively meaningless number in terms of its relevance clinical effects. The failings of J/cm<sup>2</sup>, and the importance of reporting and considering other parameters, will be addressed in a future article.

## References:

1. Physiotherapy Canada (2010) ELECTROPHYSICAL AGENTS Contraindications and Precautions: An Evidence-Based Approach to Clinical Decision Making in Physical Therapy V62/5 Special Issue.
2. Cheetham MJ, Young SR, and Dyson M. (1992) Histological effects of 820 nm laser irradiation on the healthy growth plate of the rat. *Laser Therapy*, vol. 4, no. 2, pp. 59–63.
3. Navrátil L and Kymplova J. (2002) Contraindications in noninvasive laser therapy: truth and fiction. *J. Clin. Laser Med. Surg.* 20, 341–343.
4. Mavrich VV, Luzin VI. (2000) The growth, chemical composition and strength properties of the long tubular bones in the skeleton of white rats under the influence of low energy laser radiation. *Morfologiya*. 2000;117(1):59-66. [Article in Russian]
5. Pereslytskikh PF (2008) Formation of ossification nucleus in the femoral head in hamsters exposed to laser radiation. *Morfologiya*. 2008;134(6):68-72. [Article in Russian]
6. Seifi M, Maghzi A, Gutknecht N, Mir M, Asna-Ashari M. (2010) The effect of 904 nm low level laser on condylar growth in rats. *Lasers Med Sci.* 2010;25(1):61-5.
7. Yeom M, Kim S-H, Lee B, Zhang X, Lee H, Hahm D-H, Sohn Y, Lee H. (2013) Effects of Laser Acupuncture on Longitudinal Bone Growth in Adolescent Rats. *Evidence-Based Complementary and Alternative Medicine: eCAM*, 2013, 424587.
8. Cressoni MDC, Giusti HHKD, Piao AC, de Paiva Carvalho RL, Anaruma CA and Casarotto RA. (2010) Effect of GaAlAs laser irradiation on the epiphyseal cartilage of rats. *Photomedicine and laser Surgery*, 28(4), pp.527-532.
9. de Andrade AR, Meireles A, Artifon EL, Brancalhão RMC, Ferreira JRL and Bertolini GRF. (2012) The effects of low-level laser therapy, 670 nm, on epiphyseal growth in rats. *The Scientific World Journal*, 2012.
10. de Oliveira SP, Rahal SC, Pereira EJ, Bersano PRD, Vieira FD, and Padovani CR. (2012) Low-level laser on femoral growth plate in rats. *Acta Cirurgica Brasileira*, vol. 27, no. 2, pp. 117–122, 2012.
11. Handayani S, Ramelan AH, Purwanto B, Saputra K and Tamtomo DG (2017) Histology of Epiphyseal Plate of Adolescent Rat Stimulated by Laserpuncture *J. Phys.: Conf. Ser.* 909 012092
12. Kurchenko S, Shashko A, Dudin M, Mikhailov V, Netylko G, Ashmarov V. (2012) Photodynamic impact on the epiphyseal plates. *Stud Health Technol Inform.* 2012;176:174-8.
13. Morein G, Gassnerb S, and Kplanc I. (1978) Bone growth alterations resulting from application of CO2 laser beam to the epiphyseal growth plates: an experimental study in rabbits. *Acta Orthopaedica Scandinavica*, vol. 49, no. 3, pp. 244–248, 1978.
14. Peterson HA and Wood MB. (2001) Physeal arrest due to laser beam damage in a growing child. *J. Pediatr. Orthop.* 21, 335–337.

# Contraindication or Not?

---

## *Can I laser over an infection?*

---

Here again, we can go back to a previous Four Leg blog post, packed full of juicy references!

### **Laser and Infection – Guest Blog**

<https://fourleg.com/Blog/406/Guest-Blog---Lasering-&-Infections>

Published May 4, 2019

By Peter Jenkins, MBA – [www.SpectraVET.com](http://www.SpectraVET.com)

A colleague asked me the following question:

Hey Laurie,

Do you have any experience lasering dogs with discitis? I have been looking for an article about discitis and laser and sadly there is nothing out there. I know it is ok to laser if there is an infection, however my concern is that because I do not understand what the laser does to infection cells and the infection was located within an enclosed space is there any risk of kick starting the infection.

Thanks heaps for your help 😊 x

I said that I thought it would be worth a try, but that we should submit this question to Peter Jenkins from SpectraVET. Well, Peter did not disappoint!

Hey!

I was also unable to find any papers specifically relating to discitis and laser therapy/PBM, but there are a few papers (attached) on laser/PBM therapy of similar conditions, such as osteomyelitis, and others demonstrating anti-bacterial/anti-fungal/pro-immune effects.

1: "...laser phototherapy with the appropriate irradiation parameters appears to be a promising adjunct and/or alternative technique to pharmacological agents in the treatment of osteomyelitis." <https://www.ncbi.nlm.nih.gov/pubmed/21219239>

1a (Letter to Editor re above): "...it is possible that the healing effect of 808-nm light on osteomyelitis induced in rats is not the result of *S. aureus* killing but through upregulating the immune system."

2 (only available in Russian): "It was shown that the transcutaneous infrared irradiation of the affected area during the exacerbation of chronic osteomyelitis had a well apparent immunostimulatory effect and reduced the activity of the inflammatory process." <https://www.ncbi.nlm.nih.gov/pubmed/26852503>



3: An *S. aureus* infected wound healing study in diabetic rats demonstrated "...significant bacterial growth inhibition" with PBM. <https://www.ncbi.nlm.nih.gov/pubmed/27579876>


4: PBM can "...significantly reduce the pathogenicity of *Candida albicans*." <https://www.ncbi.nlm.nih.gov/pubmed/24905928>

Basically, any proliferative effects light may have upon infectives (as demonstrated in vitro) is at least partially offset, totally mitigated, or even reversed due to the stimulatory effects of light on the host immune response.

To maximise the immune response I'd suggest irradiating accessible lymph nodes in addition to the local treatment of the spine.

Hope this helps!

Cheers!  
Peter



I thought this was brilliant as is, but he then sent more information based on a similar question from another colleague. The question was basically, 'What does current research say regarding the safety of laser over areas of active infection?'

Here's Peter's reply to that!

Although photobiomodulation (a.k.a. laser therapy, LLLT, LPLI, cold laser, etc..) has been shown to have both inhibitory and proliferative effects upon bacteria and fungal infectives *in vitro*, *in vivo* the effects are almost always inhibitory and, thus, beneficial to the patient.

For example:

1. Nussbaum et al (2003) investigated the effect of LLLT at various irradiances and exposure times on *E. coli*, *P. aeruginosa*, and *S. aureus in vitro*, and found that "E. coli growth increased", "P. aeruginosa growth decreased", and that *S. aureus* was largely unaffected.
2. Lu et al (2016) found that "...mice treated via LPLI [low-power laser irradiation] exhibited a profoundly enhanced defense against infection with *L. monocytogenes*, and both the bacterial clearance ability and the survival rate of the mice were increased under LPLI treatment.", and that "LPLI treatment augments macrophage phagocytic activity and the host defense against infection".
3. Ranjbar and Takhtfooladi (2016) studied *S. aureus* infected wounds in diabetic rats concluded that "Photobiomodulation therapy may be useful in the management of wound infection through a significant bacterial growth inhibition and an acceleration of wound healing process."
4. Kaya et al (2011) found that "...laser phototherapy with the appropriate irradiation parameters appears to be a promising adjunct and/or alternative technique to pharmacological agents in the treatment of [MRSA-induced] osteomyelitis.", and attributed the healing effect to the bactericidal effect of 808-nm diode on *S. aureus*, however...
  - 4a. Lubart (2011) suggest that, instead, "the healing effect of 808-nm light on osteomyelitis induced in rats is not the result of *S. aureus* killing but through upregulating the immune system.". [NB. a similar pro-immune effect may also be the case in 3, above, and is also discussed in 4b, below]
  - 4b. Trunova et al (2015) state, "It was shown that the transcutaneous infrared irradiation of the affected area during the exacerbation of chronic osteomyelitis had a well apparent immunostimulatory effect and reduced the activity of the inflammatory process."
5. Seyedmousavi et al (2014) concluded that, rather than posing a risk, laser PBM can "...significantly reduce the pathogenicity of *Candida albicans*" and, therefore, "...may be a promising novel treatment approach for superficial and mucocutaneous *C. albicans* infections."

Basically, any proliferative effects light may have upon infectives (as demonstrated by Nussbaum, *in vitro*) is at least partially offset, totally mitigated, or even reversed, due to the stimulatory effects of light on e.g. the host immune response.

Regarding TB, Vlassov and Reze (2006) (6) reviewed the use of low level laser therapy (LLL) as an adjunct to antituberculous drugs for treating tuberculosis. Although they concluded there was insufficient evidence at the time to support its widespread use and it "should only be used in randomized controlled trials until its value is evaluated", no adverse effects were attributed to the use of laser therapy in TB patients.

Cheers!  
Peter



### References:

**1-nussbaum2003.pdf:** Nussbaum, E. L., Lilge, L., & Mazzulli, T. (2003). Effects of Low-Level Laser Therapy (LLLT) of 810 nm upon in Vitro Growth of Bacteria: Relevance of Irradiance and Radiant Exposure. *Journal of Clinical Laser Medicine Surgery*, 21(5), 283–290.

doi:10.1089/104454703322564497 <https://www.ncbi.nlm.nih.gov/pubmed/14651796>

**2-lu2016.pdf:** Lu, C., Fan, Z., & Xing, D. (2016). Photo-enhancement of macrophage phagocytic activity via Rac1-mediated signaling pathway: Implications for bacterial infection. *The International Journal of Biochemistry & Cell Biology*, 78, 206–216. doi:10.1016/j.biocel.2016.06.010 <https://www.ncbi.nlm.nih.gov/pubmed/27345261>

**3-ranjbar2016.pdf:** Ranjbar, R., & Takhtfooladi, M. A. (2016). The effects of photobiomodulation therapy on Staphylococcus aureus infected surgical wounds in diabetic rats. A microbiological, histopathological, and biomechanical study. *Acta Cirurgica Brasileira*, 31(8), 498–504. doi:10.1590/s0102-865020160080000001 <https://www.ncbi.nlm.nih.gov/pubmed/27579876>

**4-kaya2011.pdf:** Kaya, G. Ş., Kaya, M., Gürsan, N., Kireççi, E., Güngörmüş, M., & Balta, H. (2011). The Use of 808-nm Light Therapy to Treat Experimental Chronic Osteomyelitis Induced in Rats by Methicillin-Resistant Staphylococcus Aureus. *Photomedicine and Laser Surgery*, 29(6), 405–412.

doi:10.1089/pho.2010.2807 <https://www.ncbi.nlm.nih.gov/pubmed/21219239>

**4a-lubart2011.pdf:** Lubart, R. (2011). A Possible Mechanism for Treating Staphylococcus aureus-Induced Chronic Osteomyelitis in Rats Using 808-nm Light. *Photomedicine and Laser Surgery*, 29(12), 789–790.

doi:10.1089/pho.2011.9898 <https://www.ncbi.nlm.nih.gov/pubmed/22107485>

**4b-trunova2015.pdf:** Trunova OV, Mashkov AE, Khan MA, Prikuls VF, Nazarenko NN, Supova MV, Smirnova SN, Larionov KS (2015). The application of laser therapy for the medical rehabilitation of the children presenting with chronic osteomyelitis. *Vopr Kurortol Fizioter Lech Fiz Kult*. 2015 Sep-Oct;92(5):50-53. doi:

10.17116/kurort2015550-53. <https://www.ncbi.nlm.nih.gov/pubmed/26852503>

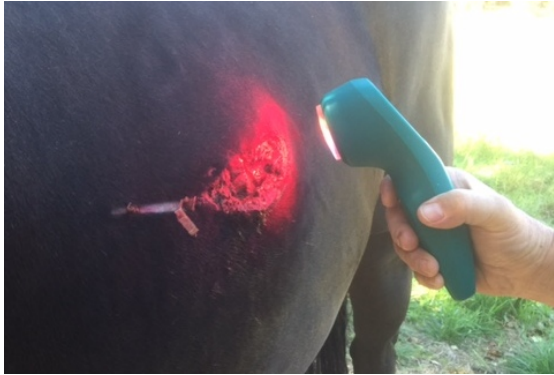**5-seyedmousavi2014.pdf:** Seyedmousavi, S., Hashemi, S. J., Rezaie, S., Fateh, M., Djavid, G. E., Zibafar, E., ... Ataie-Fashtami, L. (2014). Effects of Low-Level Laser Irradiation on the Pathogenicity of *Candida albicans*: In Vitro and in Vivo Study. *Photomedicine and Laser Surgery*, 32(6), 322–329.

doi:10.1089/pho.2012.3387 <https://www.ncbi.nlm.nih.gov/pubmed/24905928>

**6-vlassov2006.pdf:** Vlassov, V. V., & Reze, A. G. (2006). Low level laser therapy for treating tuberculosis. *Cochrane Database of Systematic Reviews*. doi:10.1002/14651858.cd003490.pub2

## *LASER Tip:* How might you laser over an oozing, weeping infection?

- Hold the probe 1cm away from the tissue
- Use plastic food wrap over the wound



## *Contraindication or Not?*

---

*Can I laser near a pregnant uterus? Can I laser the back of a pregnant dog? Can I laser iliopsoas in a pregnant dog?*

---

This question comes up frequently if your clientele consists of breeder! Lasering over or near a pregnant uterus is always listed as a contraindication, despite the fact that this has rarely been studied. Hode & Tuner in their book, *Laser Phototherapy – Clinical Practice and Scientific Background*, comment “If a complication unrelated to the use of a laser arises during or shortly after laser treatment, it is easy to blame the laser and the therapist is left with the burden of proof. It pays therefore to be prudent.”

Hode L and Tuner L. Contra indications. In: *Laser Phototherapy – Clinical Practice and Scientific Background*. 2014, Prima Books, Grangesberg, Sweden, pp. 648.

Here again, I found a paper and did a blog post on the subject!

## LASER and PREGNANCY

<https://fourleg.com/Blog/416/Laser-and-Pregnancy>

Published July 12, 2019

By Laurie Edge-Hughes

Hip-Hip-Hooray! I love when science comes out with something that either proves or disproves a commonly cited (but not proven) statement! This is one such thing. For years (decades... over half a century actually), we've been told to not laser over or near a pregnant uterus. Why? Well, no reason, just because somebody figured, 'better safe than sorry'. As such, that has been the recommendation by manufacturers and textbooks alike. However, a fresh-off-the-press systematic review gives us some up to date information on this subject!



**Wilkerson EC, Van Acker MM, Bloom BS, Goldberg DJ. Utilization of Laser Therapy During Pregnancy: A Systematic Review of the Maternal and Fetal Effects Reported From 1960 to 2017.**

**Dermatol Surg. 2019 Jun;45(6):818-828.**

<https://www.ncbi.nlm.nih.gov/pubmed/30998530>

### **Abstract**

#### **BACKGROUND:**

Due to concerns regarding maternal and fetal safety and the absence of evidence to the contrary, laser treatment during pregnancy has traditionally been limited to situations of absolute necessity.

#### **OBJECTIVE:**

This review seeks to examine the available evidence to determine the safety of laser therapy during pregnancy.

#### **METHODS:**

Medical databases were searched for relevant reports from all specialties regarding the use of lasers during pregnancy from 1960 to 2017. A legal case review was also performed.

## **RESULTS:**

Twenty-two publications in the literature reported the use of various laser wavelengths in 380 pregnant women during all trimesters. Other than 1 case of premature rupture of membranes questionably related to the laser treatment, there were no cases of maternal or fetal morbidity or mortality, premature labor, or identifiable fetal stress.

## **CONCLUSION:**

The available evidence, limited to low evidence level case reports and series, indicates cutaneous laser treatment during pregnancy is safe for both mother and fetus. Furthermore, laser physics and optics dictate there should theoretically be no risk of fetal laser exposure from commonly used cutaneous lasers.

Some of the interesting comments to come out of the Discussion within the paper are as follows:

- There are no randomized controlled trials on this subject.
- Recommended guidelines for laser therapy during pregnancy have not been established in the United States.
- In 2007, however, the European Society for Laser Dermatology reported vascular laser or intense pulsed light sources to have no direct impact on pregnancy; yet, their guidelines restricted laser treatment to the third trimester once the fetus is fully developed.

There are some interesting basic science research papers however:

- Jacques and colleagues (1987) showed in an experiment that shining light into the abdomen of certain pregnant small mammals resulted in small but significant amounts of light reaching the uterus. This may result in changes in fetal circadian rhythm and potentially affect the physiologic development of the visual system, itself, although it is unknown whether the affect would be positive, negative, or inconsequential.
- Based on a nonliving experimental model, even late gestation human fetuses can potentially see low light in utero depending on abdominal thickness and various other environmental conditions. Whether this affects development is unclear.
- Given the thickness of the pregnant abdomen (30 mm on average in humans), the uterus, and amniotic fluid, clinically meaningful laser energy is very unlikely to penetrate to reach the fetus.

However, the final conclusion and recommendations are the same – that cutaneous laser therapy treatments are safe for both mother and fetus. This is great news, because if you need to laser the lumbar spine, the iliopsoas, or an abdominal incision – you should be good to do so!

And now you know!

---

# What else can I laser?

## LASER THERAPY



Figure 17.2 Feline patient with CDS receiving transcranial PBMT with a 500 mW, 810 nm multiprobe handpiece.

- **LASER and THE BRAIN**
  - You can treat OCD, Cognitive Dysfunction, Cerebral Degeneration, Brain Injury, (& Cerebellar Degeneration)
    - 808nm Laser can penetrate through the scalp, skull, and meninges to a brain depth of 40 – 50mm
    - Low frequency pulsed light may be more effective
    - It has the potential to mitigate and even reverse progressive cerebral degeneration.
    - It can be used to treat brain injuries
    - Aim for 0.3 – 3.0J/cm<sup>2</sup> @ the target tissue / cortex!

Tedford et al 2015; Ando et al 2010; Godine 2017; Quihe et al 2012; Xuan et al 2013; Oron et al 2012; Naeser et al 2011

1. Tedford CE et al. Quantitative analysis of transcranial and intraparenchymal light penetration in human cadaver brain tissue. *Lasers Surg Med.* 2015 47(4):312-322.
2. Ando T et al. Comparison of therapeutic effects between pulsed and continuous wave 810nm wavelength laser irradiation for traumatic brain injury in mice. *Laser Med Surg.* 2010 42(6): 450 – 466.
3. Godine R. Neurological conditions. In *Laser Therapy in Veterinary Medicine: Photobiomodulation*. Reigel & Godbold eds. Wiley Blackwell, Iowa, 2017, pp 179-187.
4. Quihe W et al. Low-level laser therapy for closed-head traumatic brain injury in mice: effect of different wavelength. *Lasers Med Surg.* 2012 44(3): 218-226.
5. Xuan W et al. Transcranial low level laser therapy improves neurological performance in traumatic brain injury in mice: effect of treatment repetition regimens. *PLoS One.* 2013 8(1):e53454.
6. Oron A et al. Near infrared transcranial laser therapy applied at various modes to mice following traumatic brain injury significantly reduces long-term neurological deficits. *J Neurotrauma.* 2012 29(2): 401-407.
7. Naeser MA et al. Improved cognitive function after transcranial, light emitting diode treatments in chronic traumatic brain injury: two case reports. *Photomed Lasers Surg.* 2011 29(5): 351-358.

# What else can I laser?

**LASER THERAPY**



- Other crazy things you can laser
  - Urinary Tract Infections: 8 – 9 J/cm<sup>2</sup>
  - Otitis Externa: 3 – 4 J/cm<sup>2</sup> supf; 8 – 10J/cm<sup>2</sup> deep;  
10-20J/cm<sup>2</sup> Chronic
  - Rhinitis & Sinusitis: 8 – 10 J/cm<sup>2</sup>
  - Kidney disease: 50J/cm<sup>2</sup> to kidneys & proximal humerus
  - Bladder: Laser L2-4 for hypogastric N & S1-3 for Pelvic & Pudental Ns at 2 – 4J/cms<sup>2</sup> & 20J/cm<sup>2</sup> over caudal abdomen
  - Anal sacculitis: 4 – 8J/cms<sup>2</sup> & Anal Abscess: 8 – 10 J/cm<sup>2</sup>
  - Peri-Anal Fistula: 12 – 14J/cm<sup>2</sup>
  - Bacterial Folliculitis: 3 – 4J/cms<sup>2</sup> non-contact
  - Non-Inflammatory Alopecia: 3J/cm<sup>2</sup>

Godine 2017

Godine R. Abdominal conditions. In Laser Therapy in Veterinary Medicine: Photobiomodulation. Reigel & Godbold eds. Wiley Blackwell, Iowa, 2017, pp 169 – 178.

## My favourite laser research paper

Light, delivered transcutaneously, improves recovery after injury and suggests that light will be a useful treatment for spinal cord injuries.

- **Byrnes KR, Waynant RW, Ilev IK et al. (2005) 'Light promotes regeneration and functional recovery and alters the immune response after spinal cord injury.'** *Lasers Surg Med.* 36: 171 – 185.

This study used an 810nm, 150mW laser and provided a daily dose of 1589 J/cm<sup>2</sup> by administering the light for 2997 seconds/day. Treatment started 15 minutes after surgery and continued for 14 days.

Study: dorsal hemisection

Results: (speculated only 6% of power penetrated to the spinal cord depth). Significant increase in axonal number and distance regrowth. Suppressed immune cell activation and cytokine/chemokine expression. Return of some aspects of function to baseline levels.



*Print this newsletter and leave it sitting out!*

And a special shout out to:



**Delivering light  
...where it's needed.**

With over 17 years' experience, and globally-recognized as experts in our field, SpectraVET specializes in the design & manufacture of veterinary therapeutic lasers offering professionals the largest range of output powers and wavelengths available.

We will provide you with the best-value laser system for your specific needs, and the information you need to use it safely and effectively.

**www.spectravet.com**  
[sales@spectravet.com](mailto:sales@spectravet.com)

**SPECTRAVET**  
THERAPEUTIC LASERS



**FourLegRehabInc**

CANINE REHAB EDUCATIONAL RESOURCES

*See what else is available to learn:*

Visit [www.FourLeg.com](http://www.FourLeg.com)

Drop me a line! Send me your questions!

*Four Leg Rehab Inc*

PO Box 1581,  
Cochrane, AB, T4C 1B5  
Canada

[Laurie@FourLeg.com](mailto:Laurie@FourLeg.com)